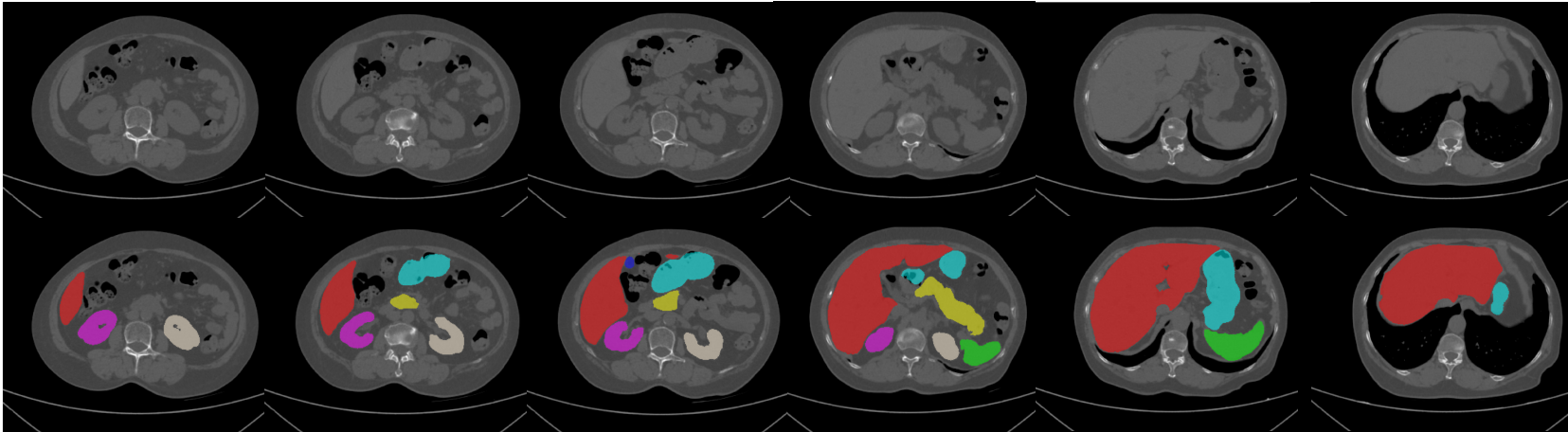


Gender: Male

Age: 31

Targets of Interests: Liver,  
Pancreas, Left Kidney, Right  
Kidney, Gallbladder, Spleen,  
Stomach

Final Report: The liver surface is smooth, and the proportions of the lobes are symmetrical, with no abnormal densities observed; the spleen is not enlarged, with uniform density; no abnormalities in the gallbladder area; no apparent abnormalities in the pancreas; the observed kidneys show no obvious abnormalities; no fluid accumulation in the abdominal cavity.



Gender: Male

Age: 38

Targets of Interests: Liver,  
Pancreas, Kidney, Gallbladder,  
Spleen

Final Report: The liver surface is smooth, the proportions of the lobes are symmetrical, and no abnormal density is observed; the spleen is not enlarged and has a uniform density; no abnormalities are observed in the gallbladder area; no obvious abnormalities are seen in the pancreas; no obvious abnormalities are observed in the kidneys seen ...

