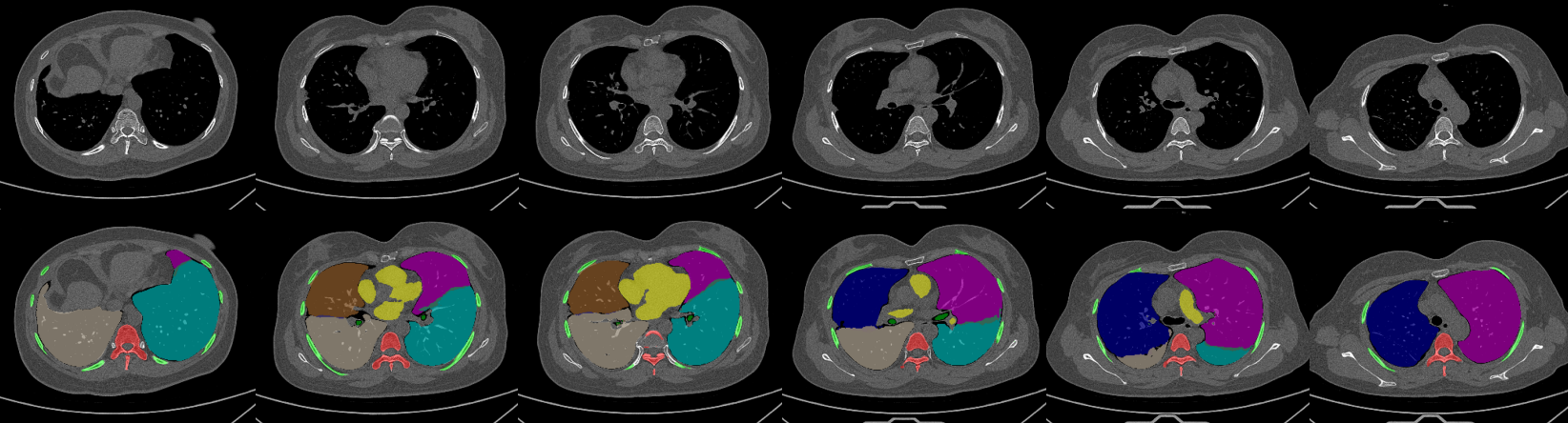


Gender: Female

Age: 34

Targets of Interests: Right lung lower lobe, Right lung middle lobe, Right lung upper lobe, Heart, Bronchi

Final Report: Follow-up after treatment for synovial sarcoma with pulmonary metastasis ... tiny nodular shadows in the lateral segment of the right middle lobe, posterior segment of the right upper lobe, and dorsal segment of the lower lobe, large solid patchy shadows in the right lower lobe. The lumens of all levels of bronchi are clear without narrowing. No obvious enlargement of the heart ...



Gender: Female

Age: 61

Targets of Interests: lumbar vertebrae L1, L2, L3, L4, L5

Final Report: The lumbar vertebrae are aligned, with straightening of the physiological curvature. There is bone spurring at the edges of the vertebral appendages. The right transverse process of L4 is discontinuous with sclerotic ends. Some intervertebral spaces are narrowed, and there is no thickening of the ligamentum flavum.

